

BIO130 Lab 7
Exercises 11& 13
in 8th, 9th, 10th Ed
Exercises 10 & 11
in 11th Edition

The Appendicular
Skeleton,
Articulations, &
Movements

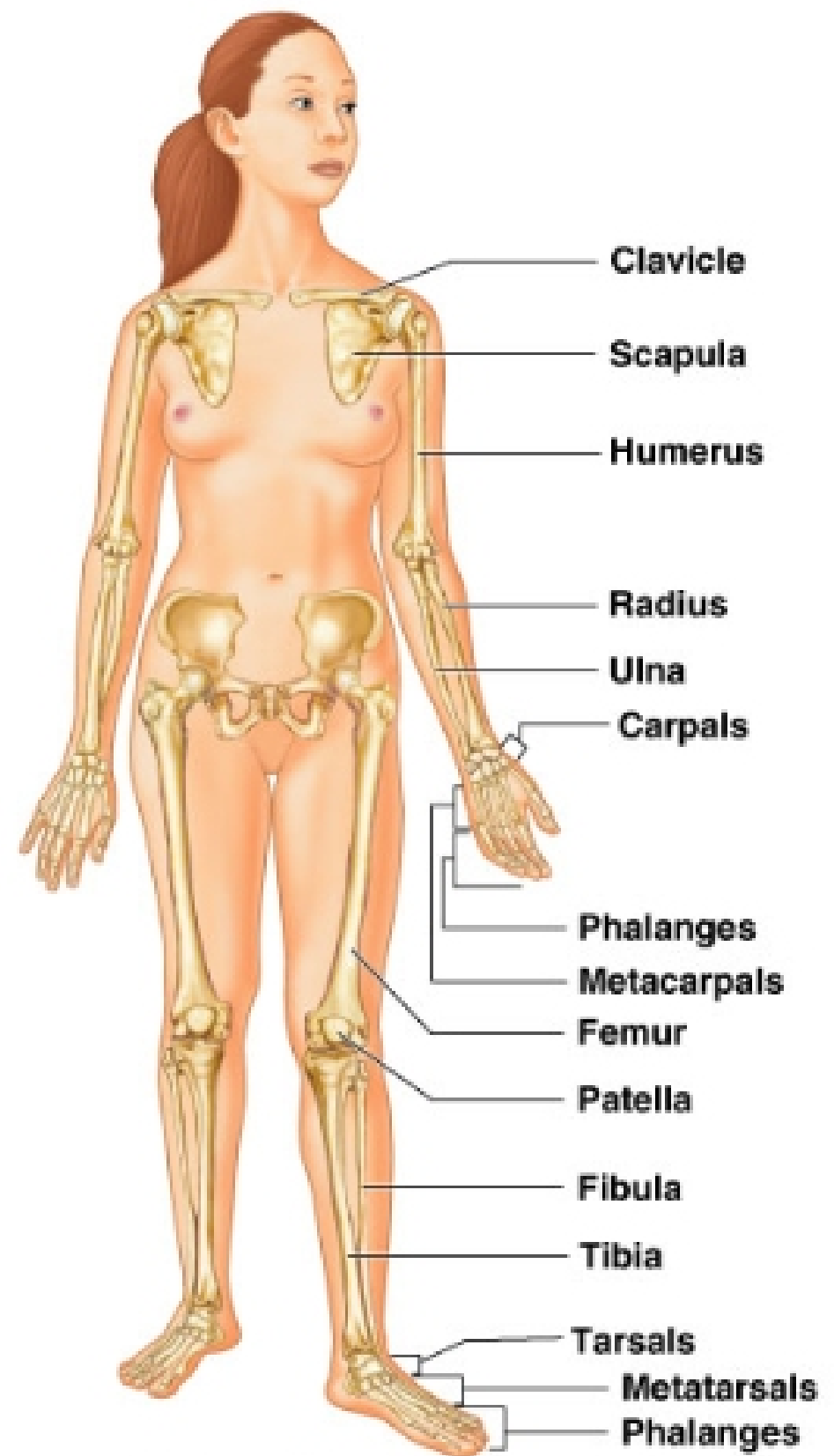


TABLE 9.1

Bone Markings

Name of bone marking	Description	Illustration
Projections that are sites of muscle and ligament attachment		
Tuberosity (too'bĕ-roz'y-tee)	Large rounded projection; may be roughened	
Crest	Narrow ridge of bone; usually prominent	
Trochanter (tro-kan'ter)	Very large, blunt, irregularly shaped process (The only examples are on the femur.)	
Line	Narrow ridge of bone; less prominent than a crest	
Tubercle (too'tur-kl)	Small rounded projection or process	
Epicondyle (ep'i-kon'dil)	Raised area on or above a condyle	
Spine	Sharp, slender, often pointed projection	
Process	Protrusion or projection	
Projections that help to form joints		
Head	Bony expansion caused on a narrow neck	
Facet	Smooth, nearly flat articular surface	
Condyle (kon'dil)	Rounded articular projection	
Ramus (ra'mas)	Armlike bar of bone	
Depressions and openings allowing blood vessels and nerves to pass		
Meatus (me-a'tas)	Canal-like passageway	
Fossa (fos'sah)	Shallow, basinlike depression in a bone, often serving as an articular surface	
Groove	Narrow	
Fissure	Narrow, slitlike opening	
Foramen (fo-ra'men) (plural: foramina)	Round or oval opening through a bone	

Table 9.1 in 8th, 9th, and 10th ed Table 8.1 in 11th edition

Help with terminology:

*Foramen = hole

*Process =

projection

etc.

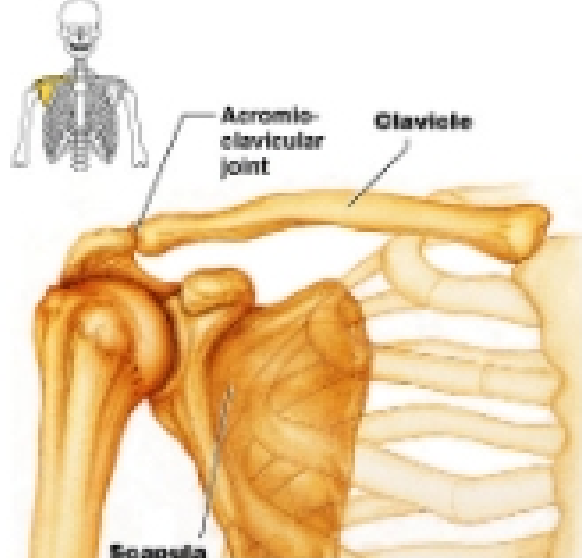



Figure 11.2 in 8th, 9th, 10th
Figure 10.2 in 11th edition

(a) Articated pectoral girdle
Copyright © 2004 Pearson Education, Inc., publishing as Benjamin Cummings.

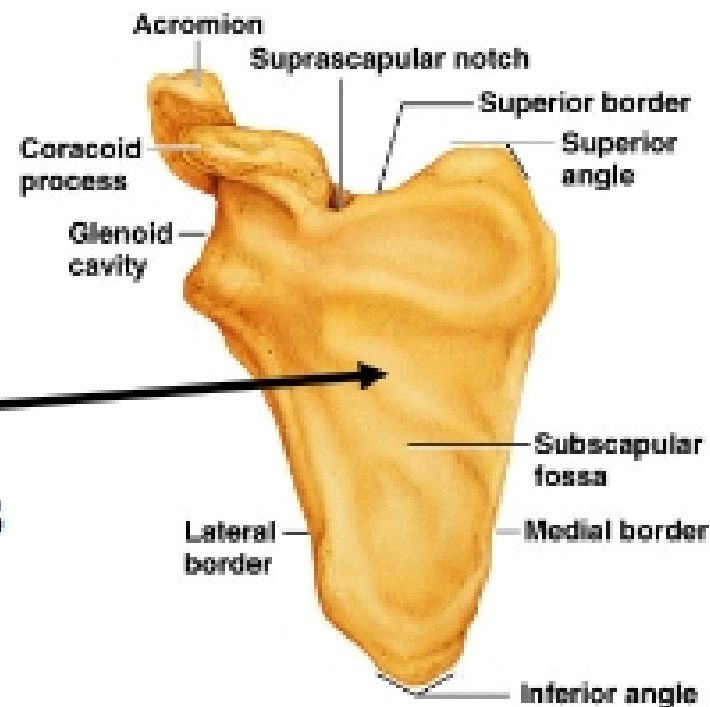


(b) Right clavicle, superior view

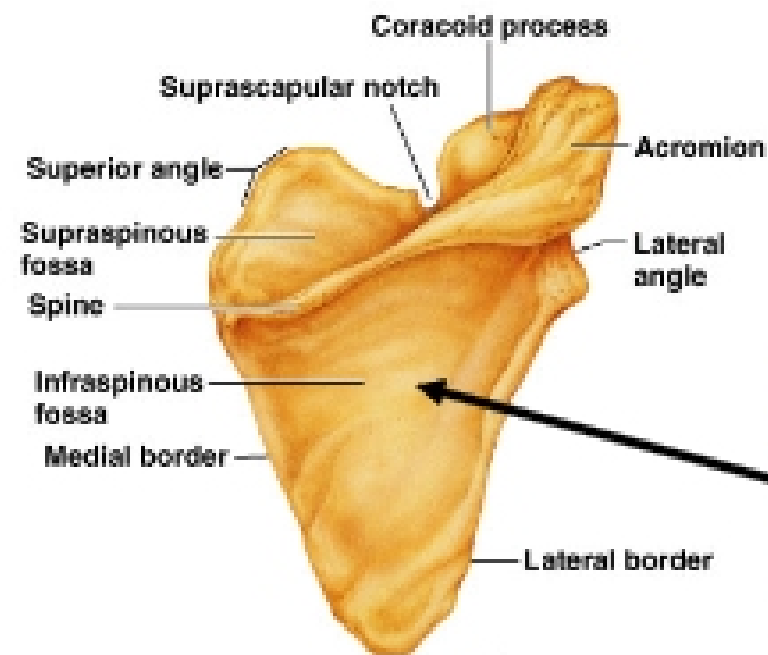


(c) Right clavicle, inferior view

- *Sternal end is blunt, square
- *Acromial end is flat
- *Superior is smooth
- *Inferior has ridges and grooves



(d) Right scapula, anterior aspect



(e) Right scapula, posterior aspect

Inside, facing ribs flat

Outside, facing back has spine