

*collagen*→protein making up fibers in connective tissue

*ligaments*→thickening of connective tissue connecting bone to bone

*tendons*→thickening of connective tissue connecting muscle to bone

*aponeurosis*→broad, flattened tendon

*fascia*→compact connective tissue membrane investing the body

*sagittal plane*→vertical, left and right portions

*median/midsagittal plane*→vertical, equal left and right portions

*frontal/coronal plane*→vertical, anterior and posterior portions

*transverse/cross-sectional/horizontal plane*→horizontal, superior and inferior portions

*endoderm*→innermost layer, inner linings of tubular structure

*mesoderm*→middle layer, muscles and connective

*ectoderm*→outermost layer, skin and nervous system

*epidermis*→outermost skin layer, no blood vessels, four layers:

*stratum corneum*→dead cells (most superficial)

*stratum lucidum*→continuously become s. corneum as keratin forms in its cells

*stratum granulosum*→cell nuclei die here

*stratum germinativum/basale*→mitosis occurs here to make new cells, melanocytes found here to produce melanin which determines skin color (most deep)

*sweat (sudoriferous) gland*→secretes onto epidermis via ducts and pores; helps to excrete wastes and salt; helps cool body when sweat evaporates

*dermis*→deep to epidermis, well supplied with blood vessels, nerve, lymph vessels, sebaceous (oil) glands, and sweat glands; hair follicles located here

*sebaceous (oil) gland*→empty sebum (oil) into hair follicles

*hair root*→part of hair implanted in dermis (above skin it is called the shaft); when arrector pili muscles contract hair stands erect (goose bumps).

*hair follicle*→inner layer (bulb) gives rise to hair; outer layer (papilla) is connective tissue of the dermis

*capillary network*→found in dermis; provides blood to epidermis by diffusion; dilation of these vessels help cool body

*osteology*→study of bones

*functions of the skeleton*→support, movement, protection, storage of minerals, production of blood cells

*axial skeleton*→skull, vertebrae, ribs and sternum; everything else→*appendicular skeleton*

*long bones*→femur, humerus, tibia

*short bones*→carpals, tarsals

*flat bones*→ribs, sternum, bones of the skull

*sesamoid bones*→grow within a tendon; patella

*irregular bones*→vertebrae, os coxae

*osteocytes*→mature bone cells

*osteoblasts*→bone cells that build new bone

*osteoclasts*→bone cells that break down bone

*epiphyseal line*→where the epiphysis and diaphysis fuse after the cartilaginous epiphyseal plate is no longer needed to grow

*spongy (cancellous) bone*→contains red bone marrow; blood cell production

*compact bone*→external coat of solid bone

*periosteum*→fascial covering found on all bones

*yellow marrow*→mostly fat; some osteoclasts found here

*arthrology*→study of joints

*bone markings: sites of muscle and ligament attachment*

*tuberosity*→large round projection

*crest*→narrow ridge

*trochanter*→very large, blunt process

*line*→narrow ridge

*tubercle*→small rounded projection

*epicondyle*→raised area on or above condyle

*spine*→slender, pointed projection

*bone markings: projections that help form joints*

*head*→bony expansion carried on narrow neck; articular

*facet*→smooth, flat, articular surface

*condyle*→rounded articular projection, joined directly to shaft of long bone

*ramus*→armlike bar

\**articular* refers to a joint, so these indicate where bones are joined\*

*bones markings: cavities*

*sinus*→space within bone; filled with air and lined with mucous

*bone markings: depressions and openings allowing blood vessels and nerves to pass*

*meatus*→canal-like passageway

*fossa*→shallow depression; often an articular surface

*groove*→furrow

*fissure*→narrow, slitlike opening

*foramen*→round or oval opening/hole through a bone

*fibrous (synarthroses—immovable) joints*→connected by fibers

*suture*→held tightly with little fiber; between cranial skull bones

*syndesmosis*→slightly longer fibers; distal tibiofibular joint

*gomphosis*→between tooth root and skull

*cartilaginous (amphiarthroses—slight movable) joints*→connected entirely by cartilage

*synchondroses*→hyaline cartilage; epiphyseal plates

*symphyses*→fibrous cartilage; pubic bones, intervertebral disks

*synovial (diarthroses—freely movable) joints*→named on basis of movement; most extremity joints

*plane*→small surfaces slide/glide on each other; facets of vertebrae

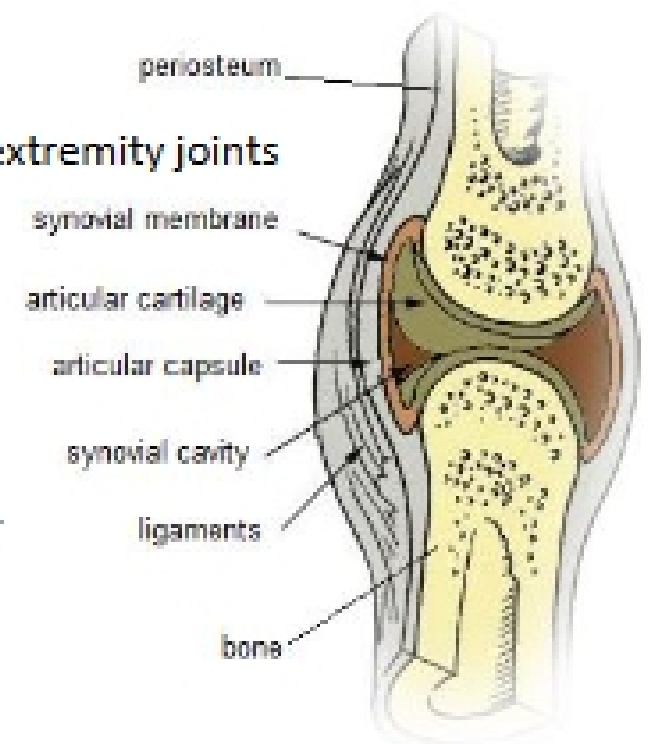
*hinge*→movement in one plane; knee

*pivot*→movement around a single axis; first cervical vertebra

*condyloid*→two directions of movement; wrist

*ball and socket*→move in many axes with common center; hip, shoulder

*saddle*→movement in two planes; carpometacarpal joint of thumb



*four characteristics of synovial joints*

*synovial cavity*→synovial fluid; reduces friction of movement

*articular cartilage*→form of hyaline cartilage; provides protection for end of bones during movement

*synovial membrane*→lines the cavity; produces synovial fluid

*articular capsule*→thickened continuation of periosteum surrounding the joint

*myology*→study of muscles

*functions of the muscles*→ability to contract (shorten its length) causing:

*production of movement*→walking, movement along GI tract, changes in blood vessel and pupil size

*production of heat*→mechanical contraction maintains body temperature

*maintaining posture*→partial contraction by skeletal muscle—*tonus*—holds body stationary

*cardiac muscle*→striated, involuntary; located within heart

*smooth (visceral) muscle*→non-striated, involuntary; located around blood vessels and organs

*skeletal muscle*→striated, voluntary; attach to bones allowing for conscious movement; major type of muscle within the limbs

*compartments*

*belly*→central, fleshy portion responsible for contraction

*origin*→tendon or muscle attachment usually more proximal; less movable

*insertion*→tendon or muscle attachment usually more distal; more movable

*connective tissue coverings of a skeletal muscle*

*epimysium*→surrounds muscle belly

*perimysium*→surrounds bundle of muscle fibers (fascicle)

*endomysium*→surrounds individual muscle fiber