

## Vertebral Column

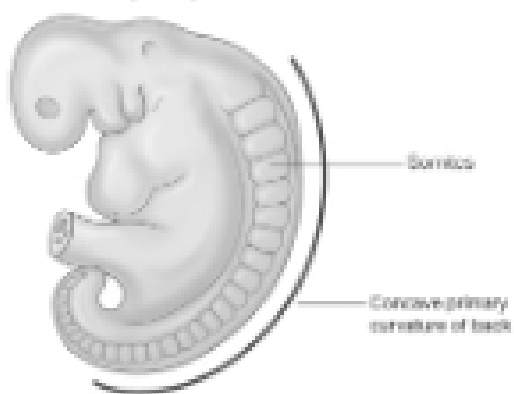
Osteology and Arthrology

## Osteology

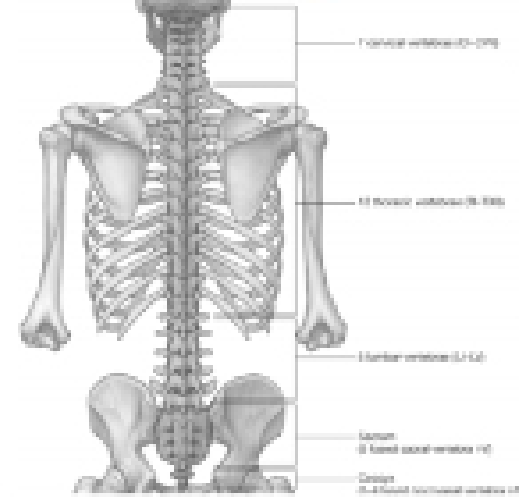
- 7 C, 12 T, 5 L, 5 S (Fused as Sacrum), 4 coccygeal
- Primary Curves
- Secondary Curves
- Anterior/Posterior alignment

## Primary Curve

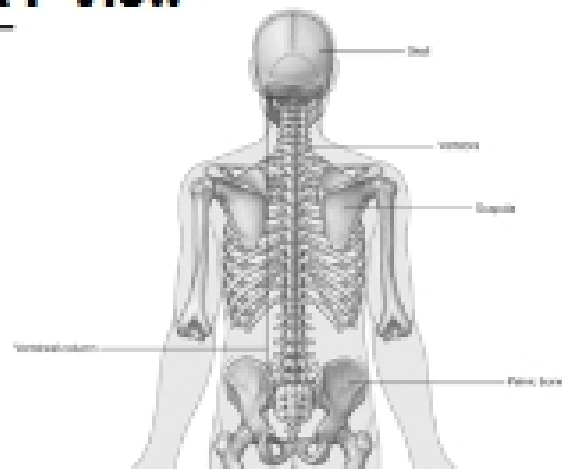
Early embryo



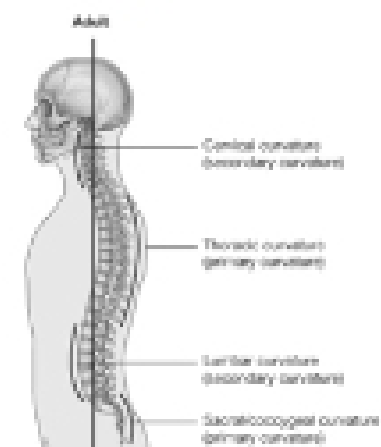
## Vertebral Segments



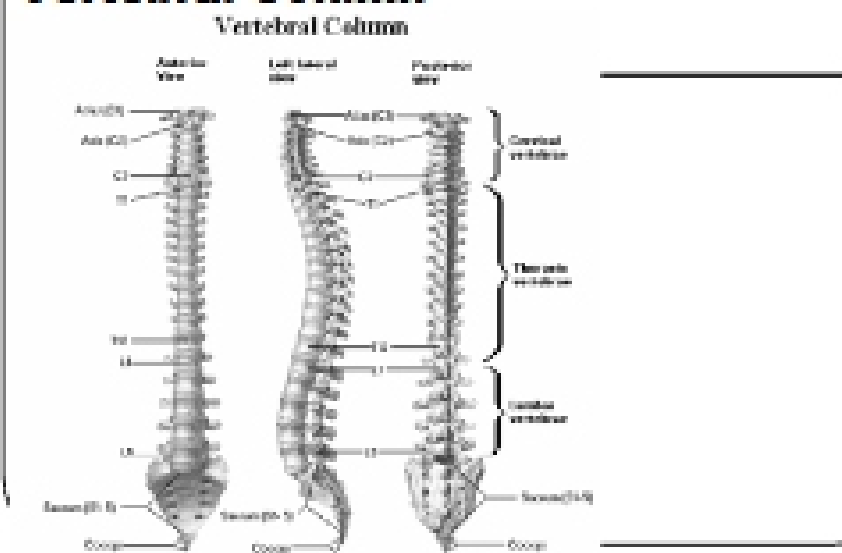
## A-P View



## Secondary Curves Lateral



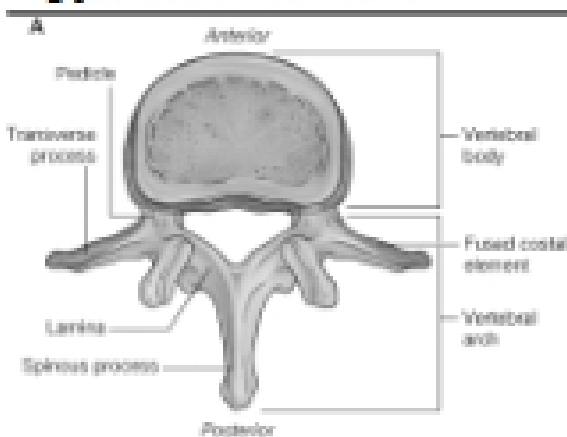
## Vertebral Column



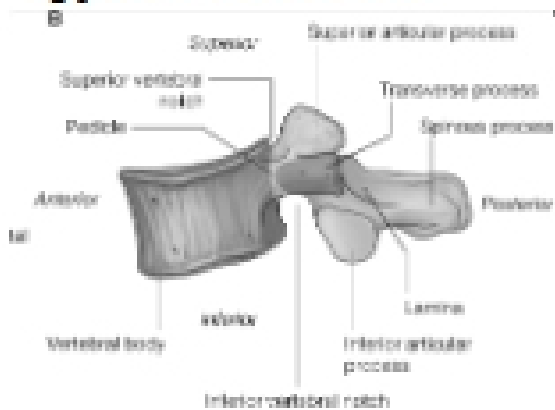
## Osteology

- Typical Vertebrae
- Body
  - Superior and inferior surfaces of body (plateaus)
  - Thickened around the rim, location of epiphyseal plates
  - Cartilaginous end-plates
- Vertebral Arch
  - Pedicles, Laminae
  - Transverse Processes
  - Spinous Process
  - Facets – superior articular and inferior articular
- Spinal Foramen
- Intervertebral Foramen

## Typical Vertebrae

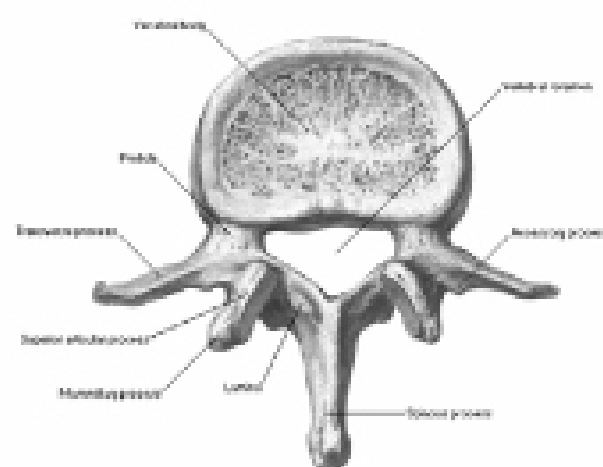


## Typical Vertebrae



## Typical Lumbar

Lumbar Vertebrae [L2]  
Superior View



## Typical Thoracic

Thoracic Vertebrae [T12]  
Lateral View

