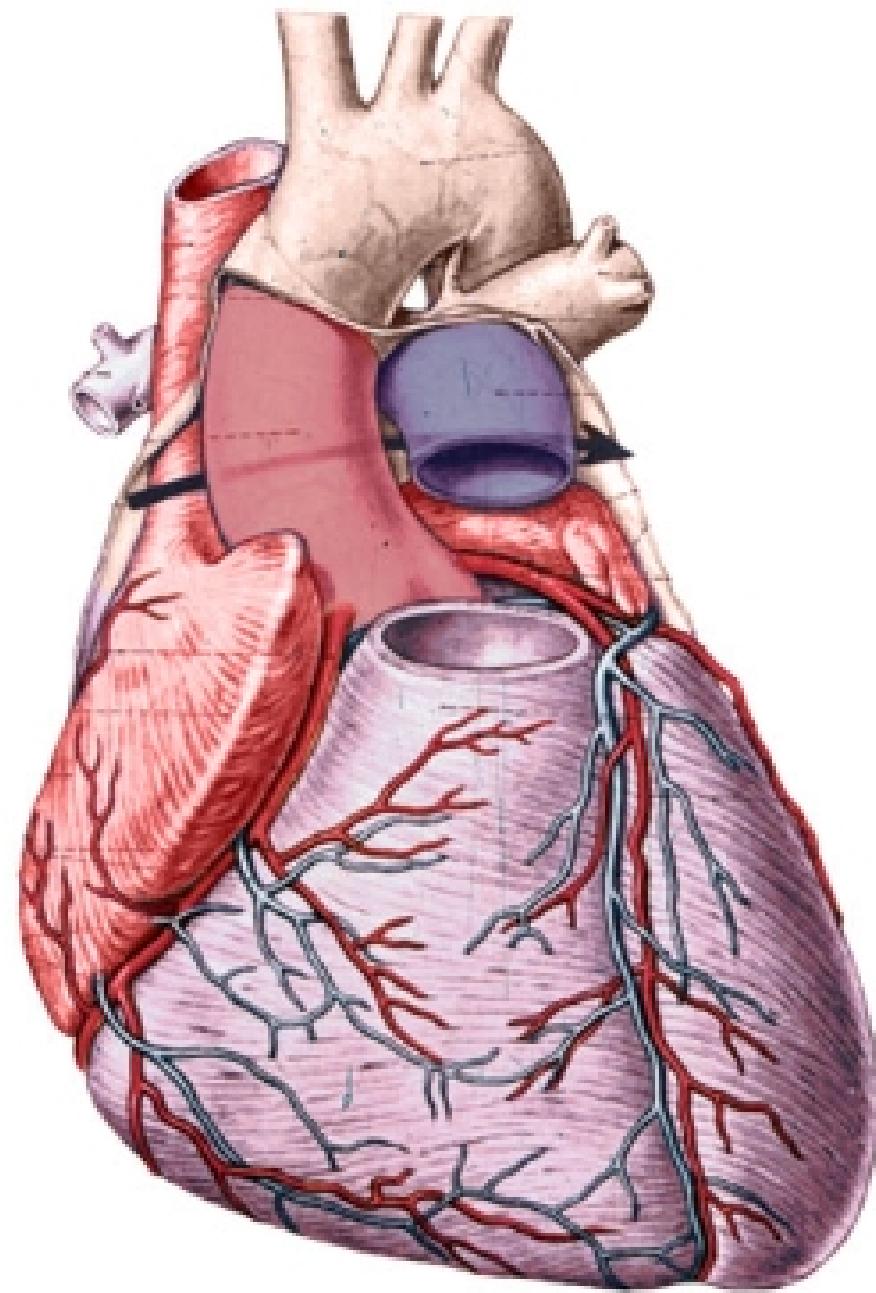
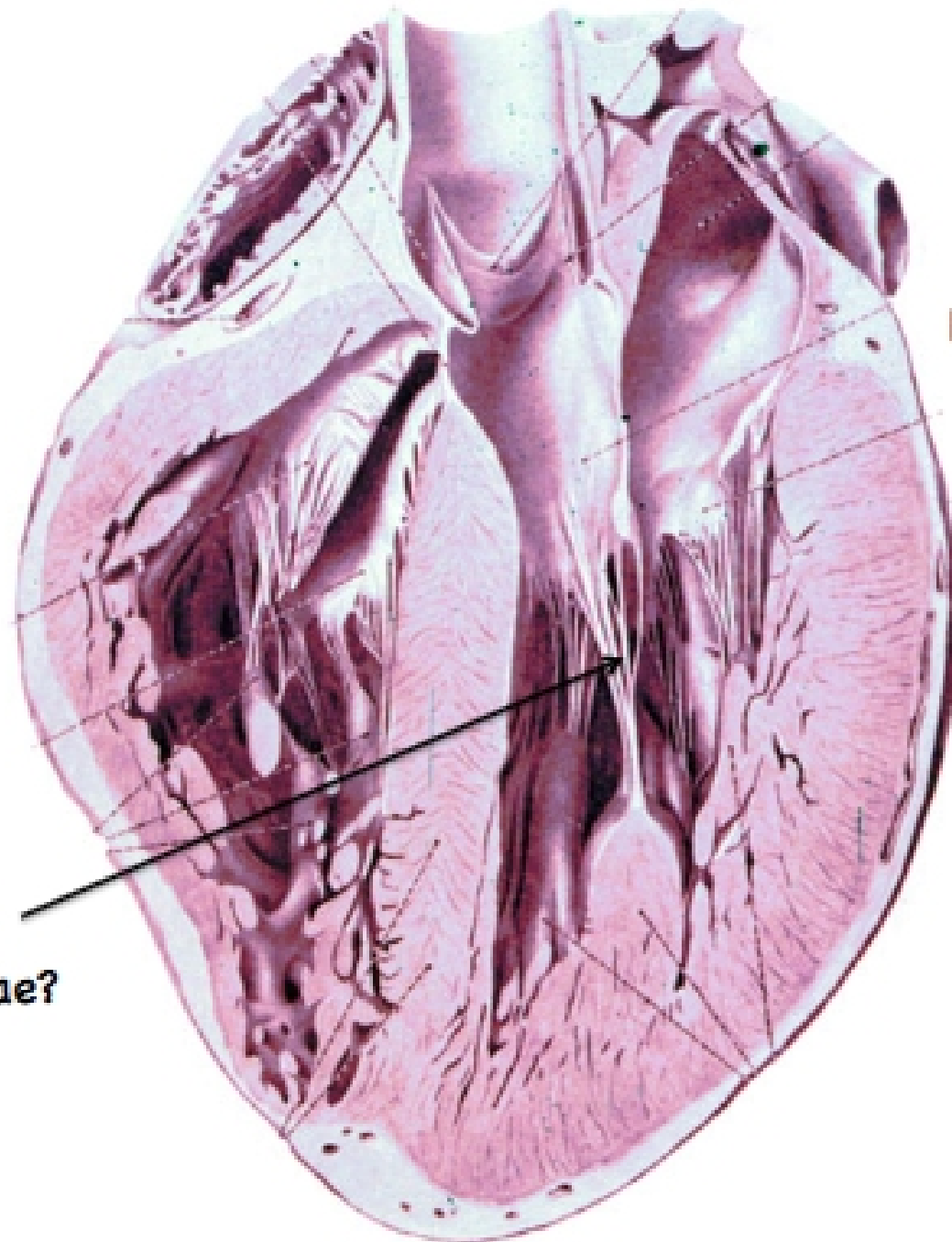


A215 Lab

Circulatory: Heart





Left ventricle thicker than right??

Function of Chordae Tendinae?