



HUMAN  
ANATOMY

*Seventh Edition*

MARTINI  
TIMMONS  
TALLITSCH

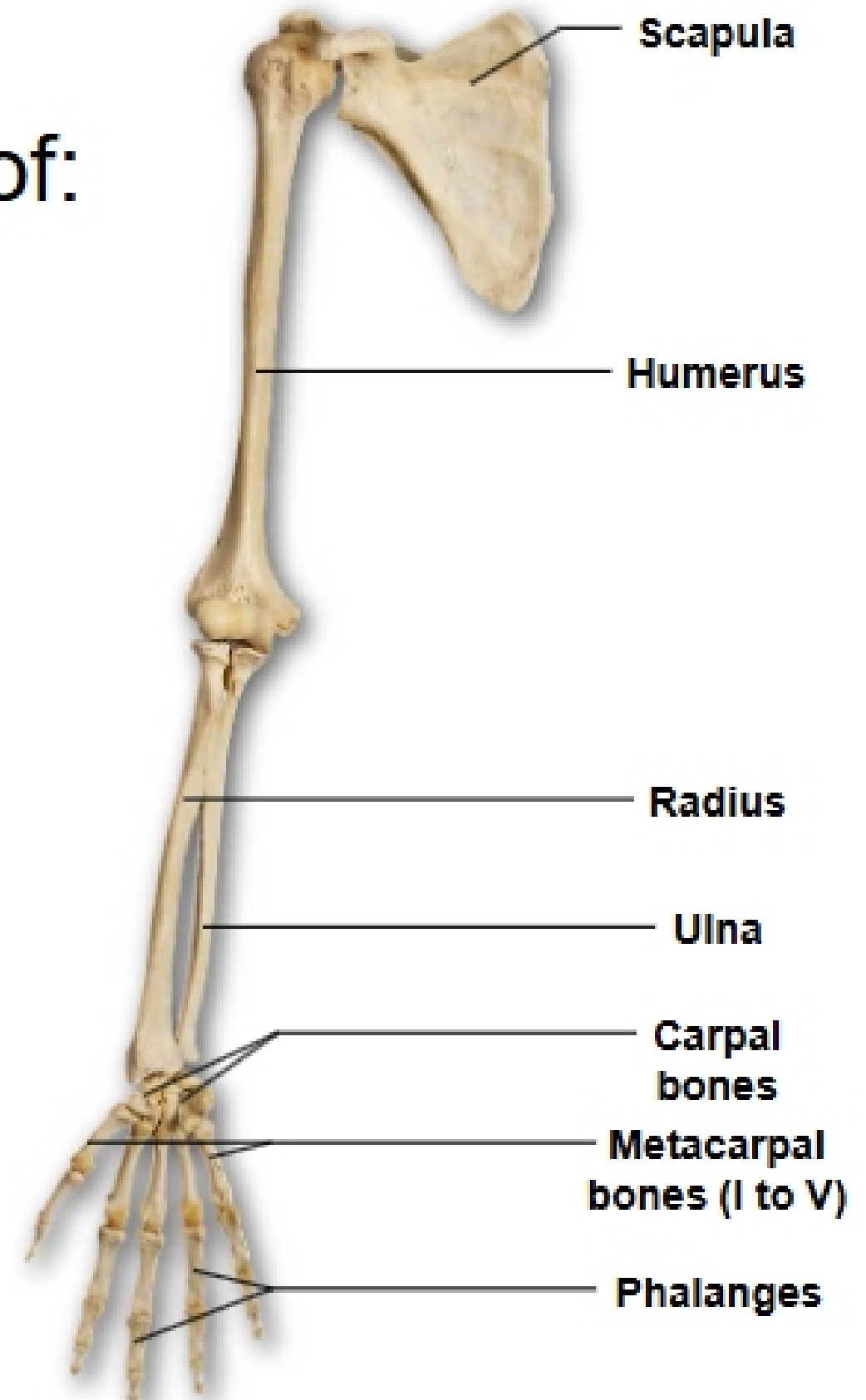
7

**The Skeletal System:  
Appendicular Division**

**EXAM #1**

**This Friday!**

- Pectoral girdle consists of:
  - **Clavicle**
  - **Scapula**
- Upper limb consists of:
  - Humerus**
  - Radius**
  - Ulna**
  - Carpals**
  - Metacarpals**
  - Pollex and other digits**



**a** Right upper limb, anterior view

## • The Clavicle

- S-shaped bone connects the scapula to the manubrium of the sternum
  - It extends from the manubrium of the sternum, lateral to the acromion process of the scapula

