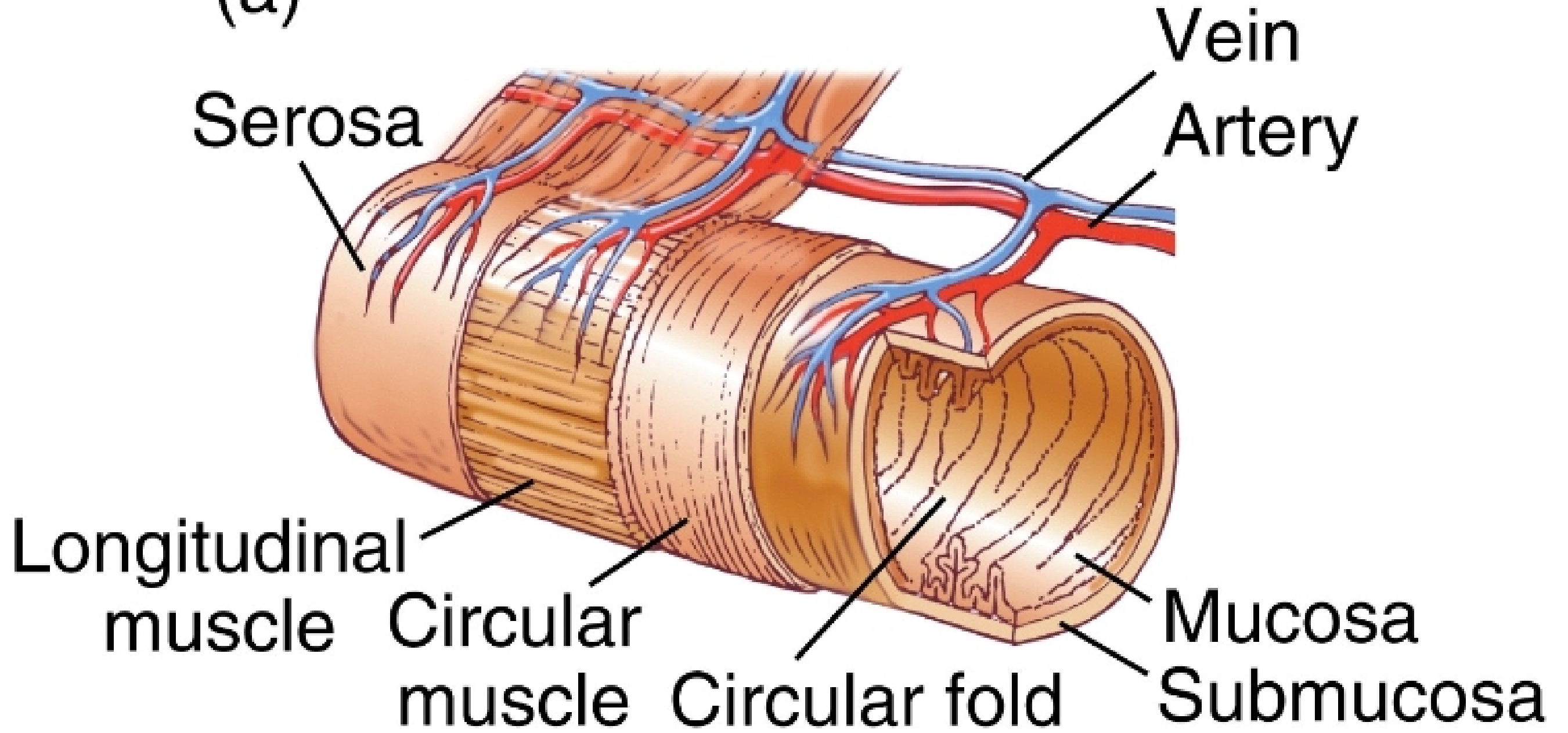


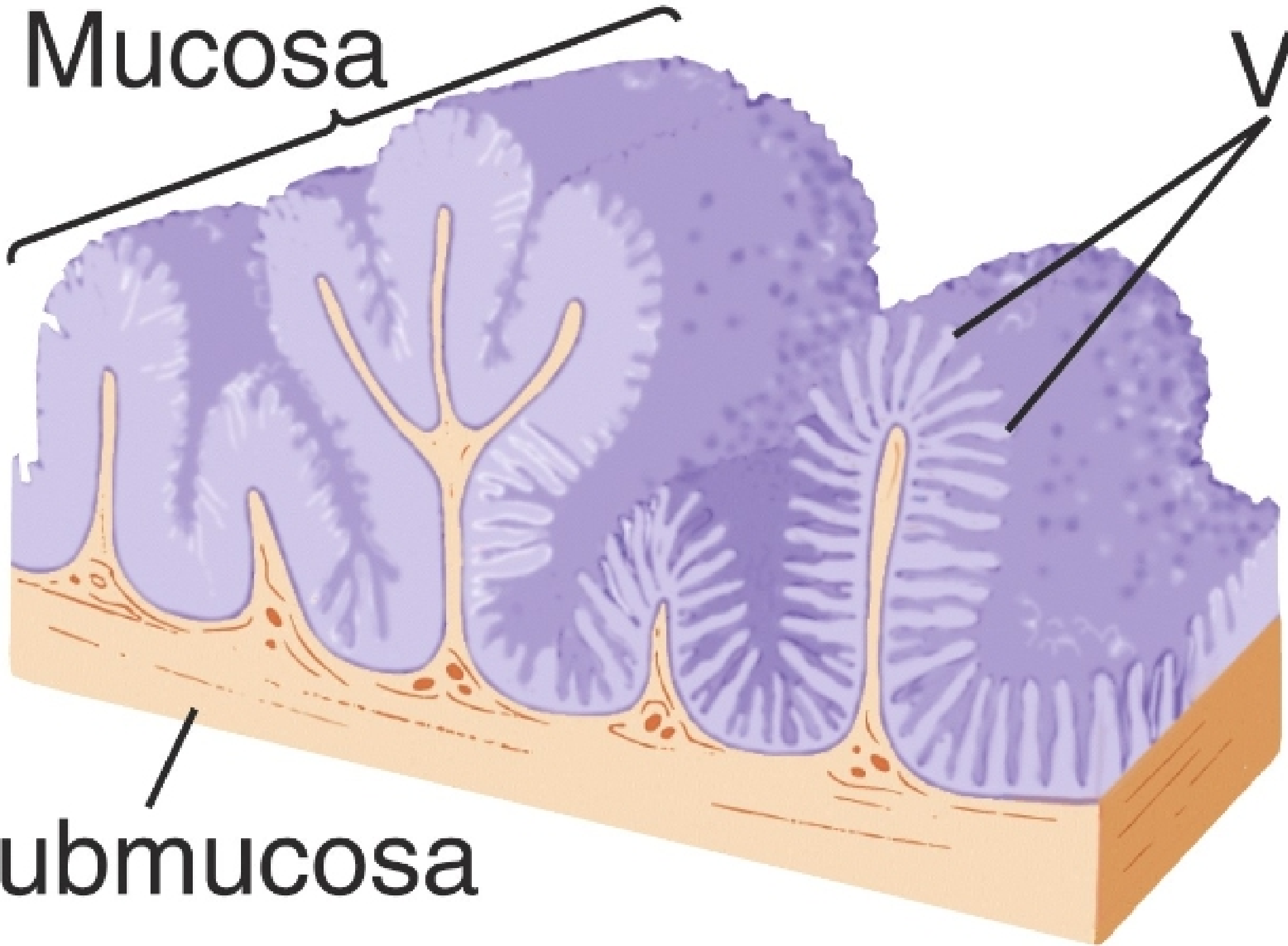
(a)



(b) Mucosa

Villi

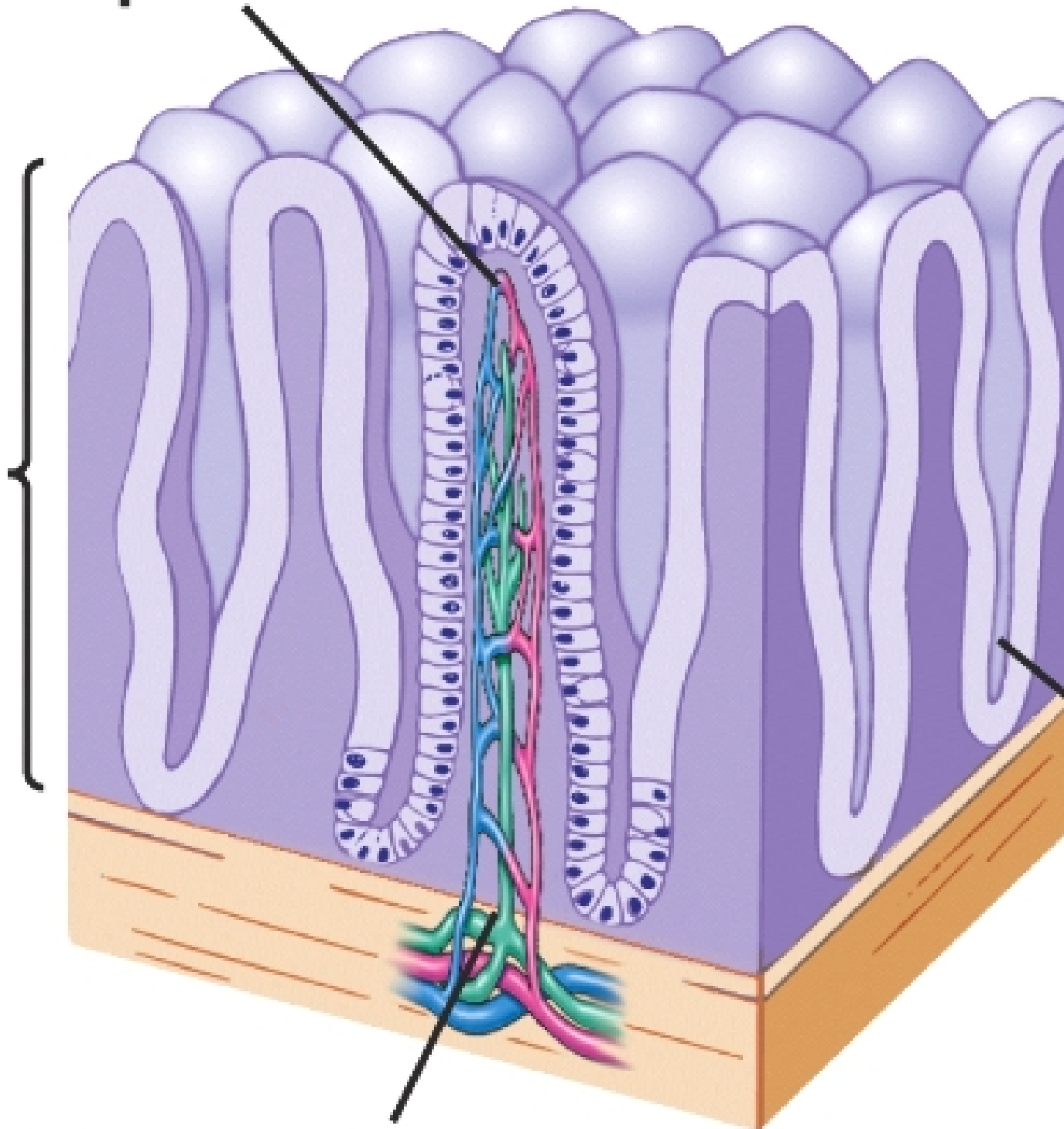
Submucosa



(c)

Capillaries

Villus



Crypt of
Lieberkühn

Central lacteal