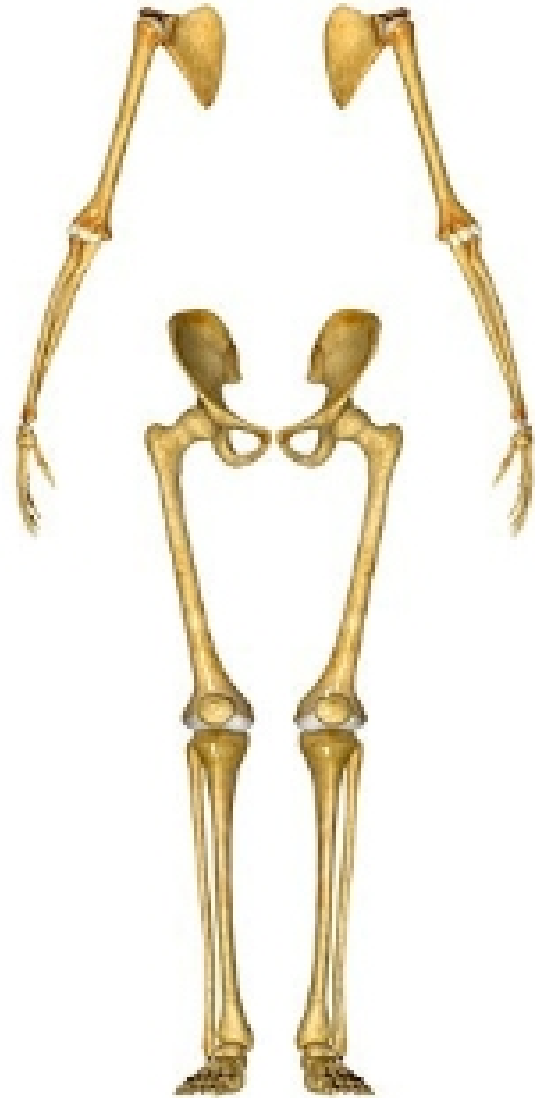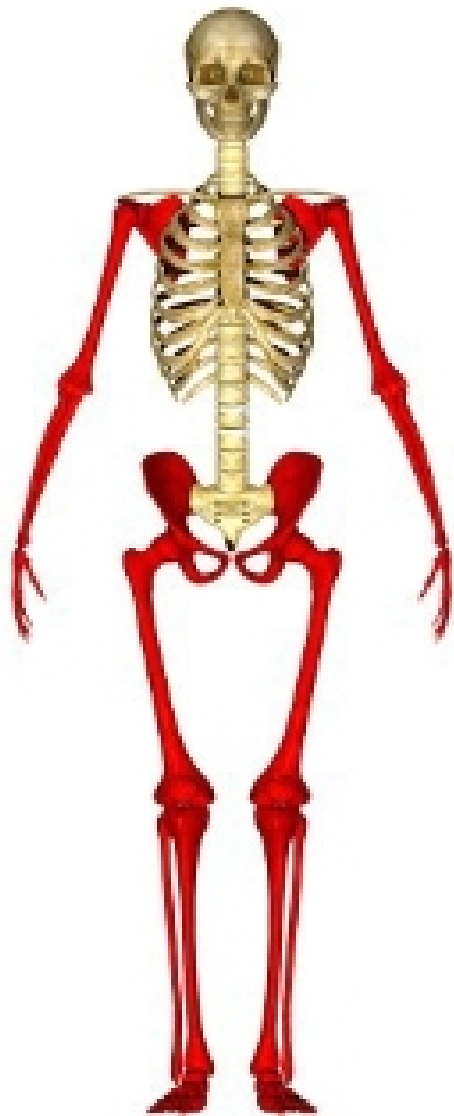


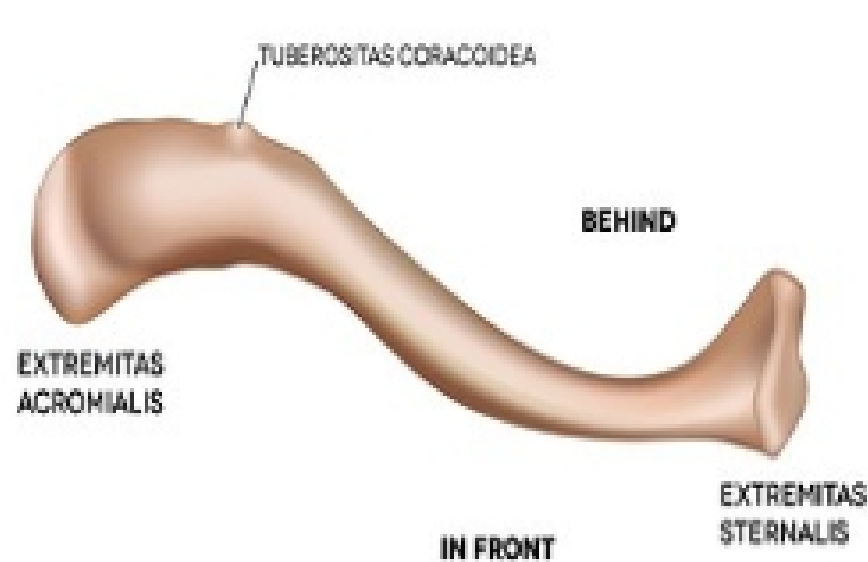
# Practical

Exercise 6 & 7

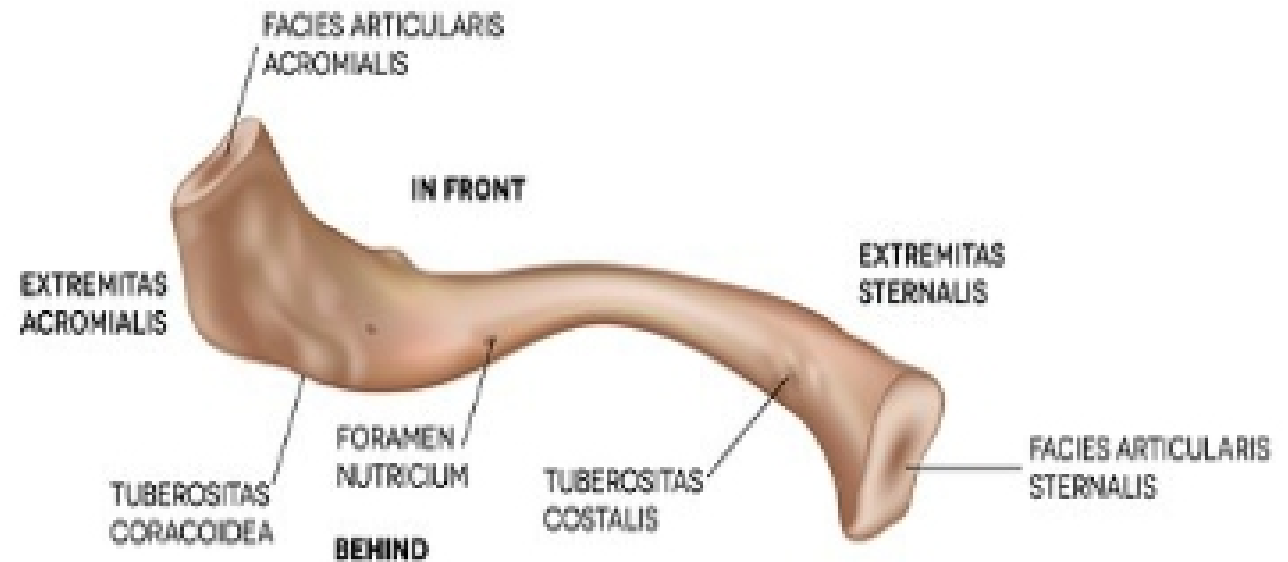
Axial skeleton a) axial skeleton (in yellow) and appendicular skeleton (in red); b) appendicular skeleton (axial skeleton removed)



# Superior and Inferior Views



FROM ABOVE



FROM BELOW