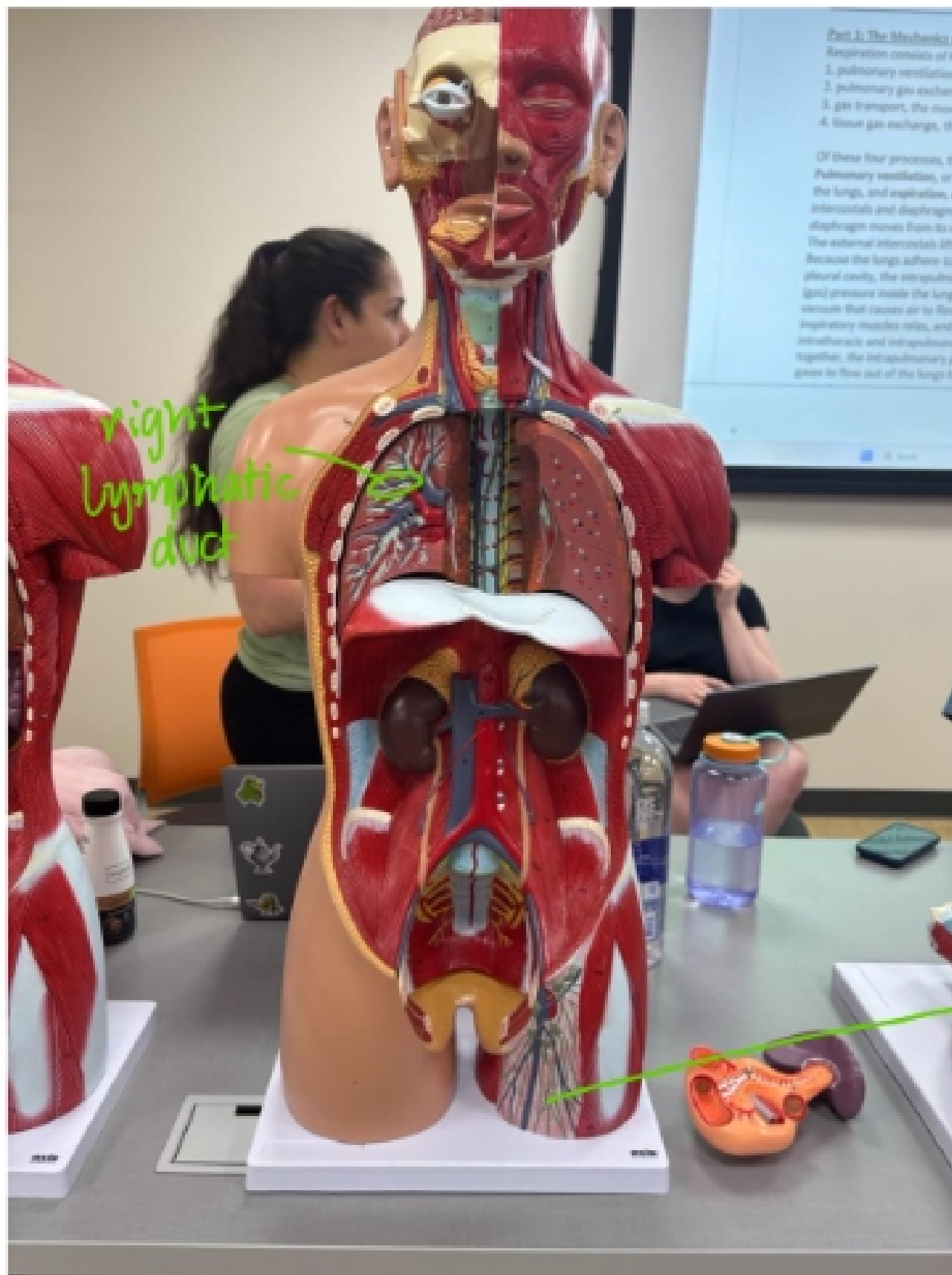


## Lymphatic Anatomy Practice

Take pictures of the following models and identify the lymphatic structures that we note on the Lymphatic list.

Torso Model:

1. **Blood vessels** heart the lymphatic duct that drains into the blood. (large)



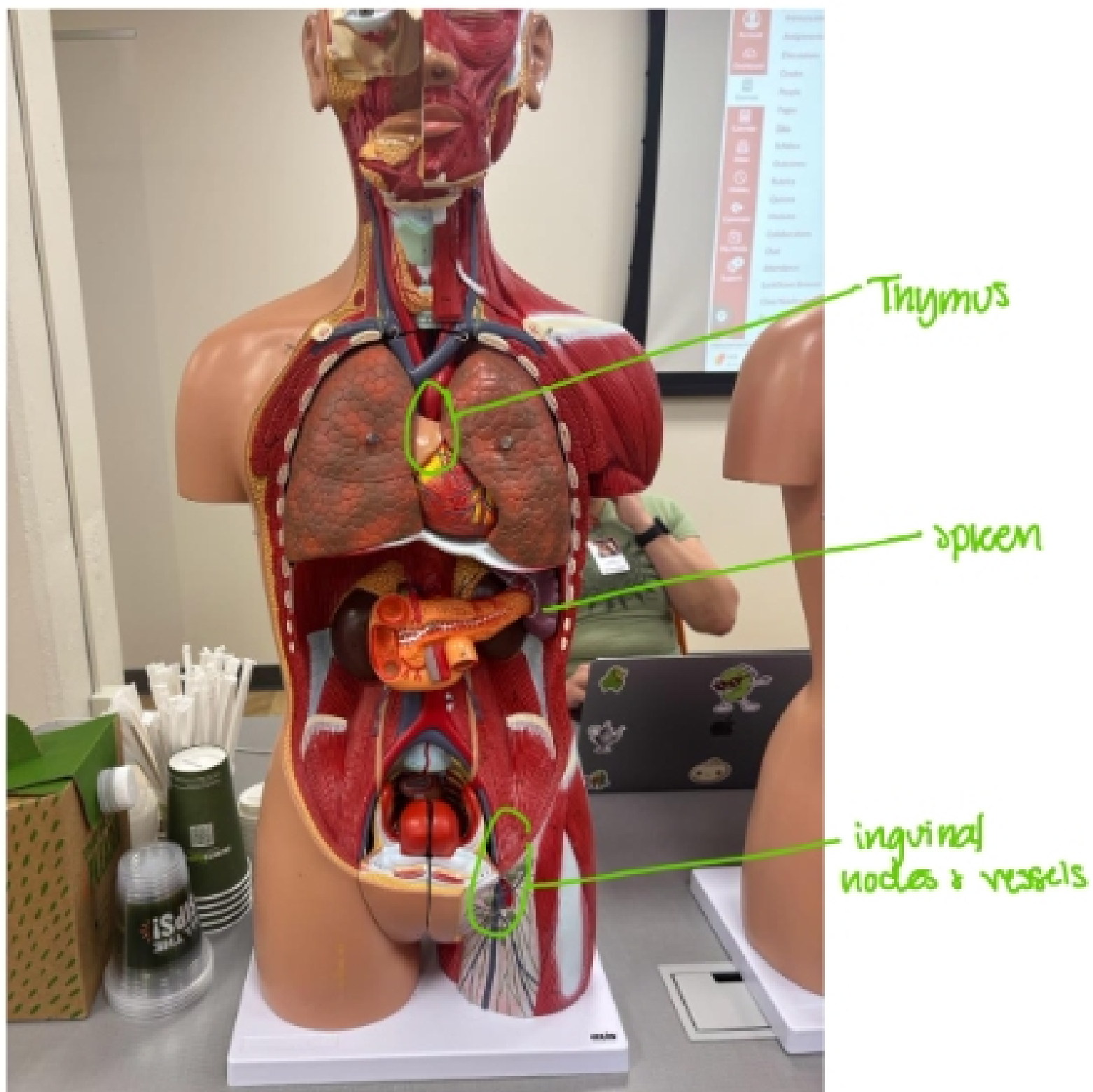
2. Torso model (large that have some of the lymphatic organs)

Inguinal nodes and vessels (know the other regions where nodes are found)-label the regions by circling the region and naming it.

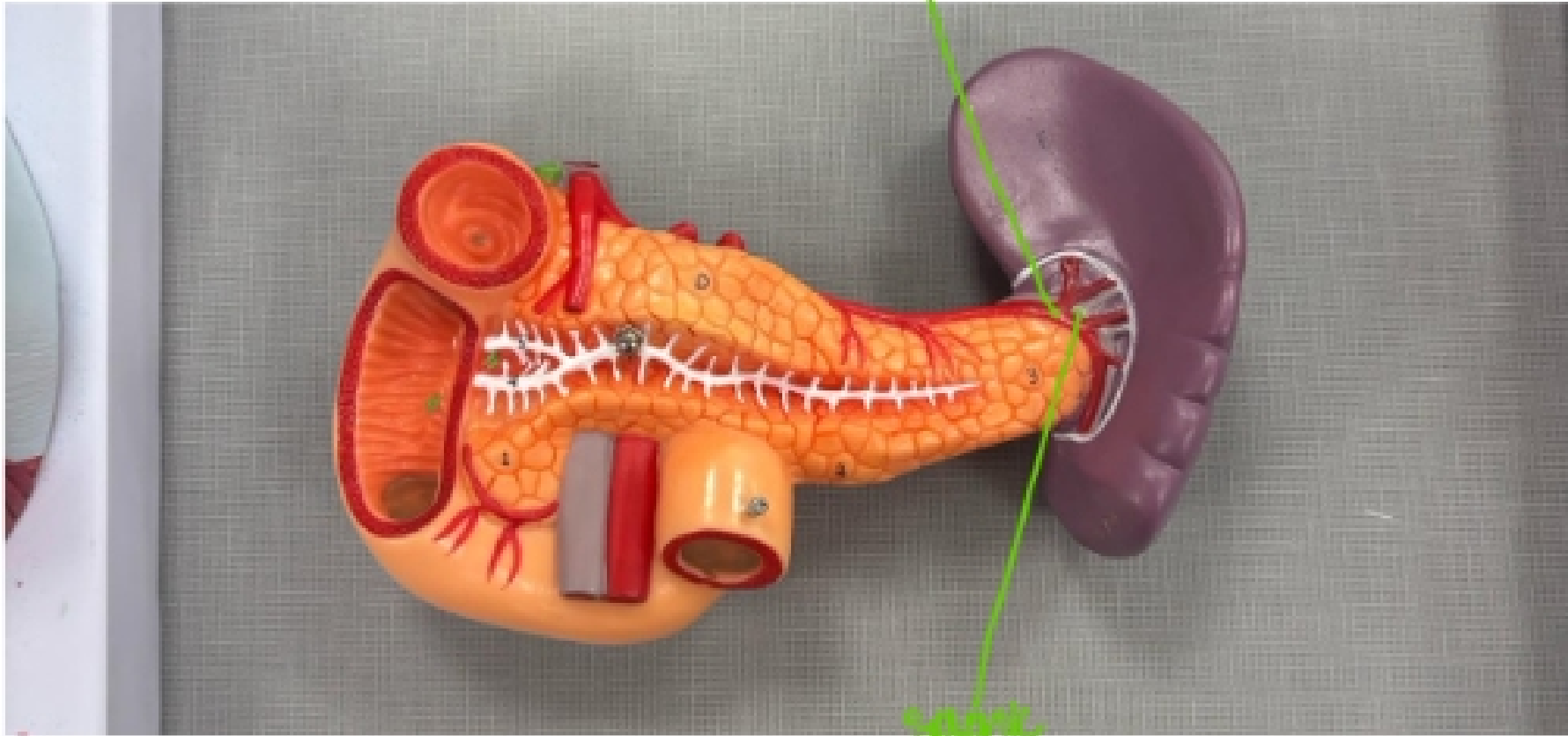
Region for the Thymus

Spleen- Splenic artery, splenic vein, celiac trunk for the splenic artery (anterior vessel) -- - (splenic vein-inferior mesenteric vein- superior mesenteric vein- hepatic portal vein-liver) (the hilum is the region where the blood vessels enter or leave the spleen)

Appendix- location and association with MALT



Splenic artery



Splenic vein