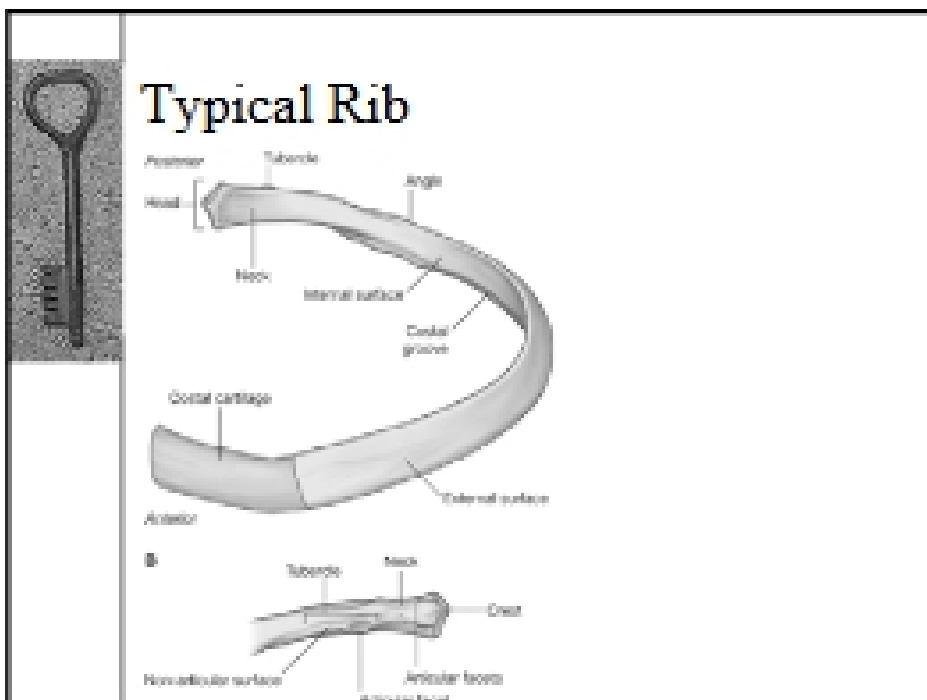



**Arthrology**

- ◆ Typical Rib
- ◆ Head (two facets)
- ◆ Neck
- ◆ Tubercle (facet)
- ◆ Angle
- ◆ Proximal end – costal cartilage

**Anterior articulations of ribs**

- ◆ Rib 1 to sternum (manubrium)
  - Fibrous joint
  - No movement
- ◆ Ribs 2 – 7 true ribs
  - Synovial (gliding) joints
  - Radiate sternocostal ligaments
- ◆ Ribs 8-10 = false, articulate with 7
- ◆ 11-12 = floating

